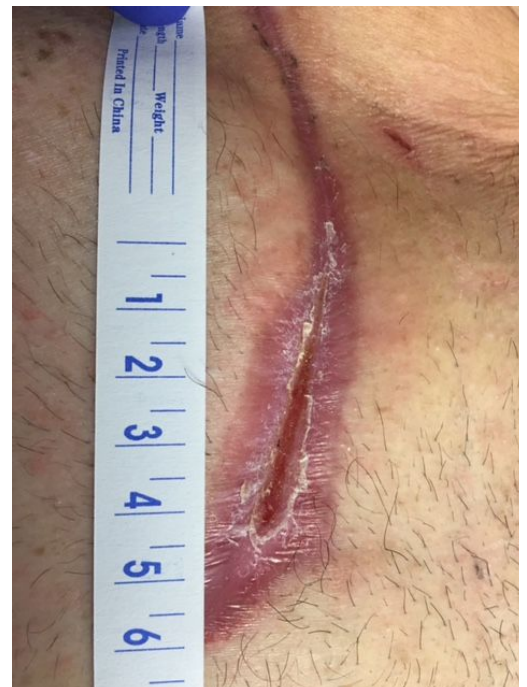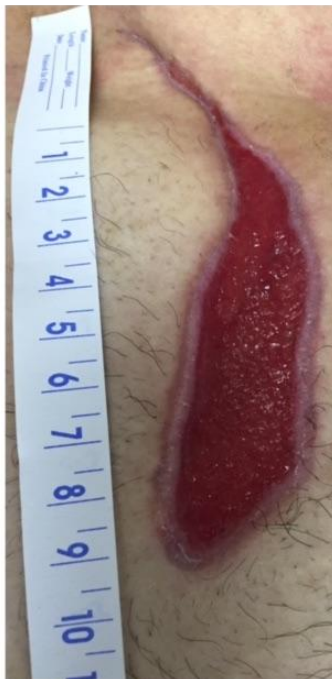

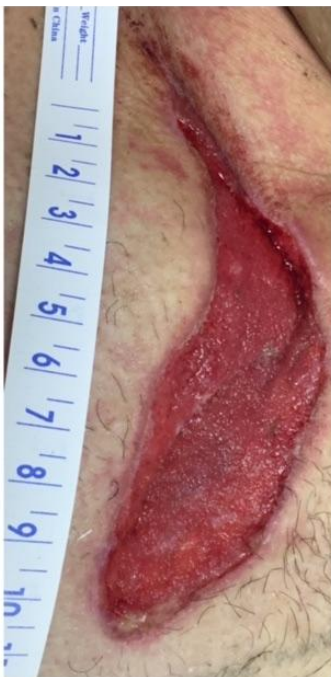


Safe • Effective • Trusted

- 36 Year Old Previously healthy Male Presented with 2 week history of pain in right chest and neck, fever.
- Febrile to 101 degrees, 14,000 WBC, CT of Chest revealed air in soft tissue of chest into right neck.
- Taken urgently to surgery for radical debridement and packing. (Cultures of Wound and Blood, MSSA)
- Monitored in the NTICU and taken back 48 hours later for second look and Placement of VAC.
- Discharged home on IV antibiotics and Home VAC.



<p>Day of VAC Removal (12 days post-discharge)</p> <p>Total Wound Size: Approx. 332 cm</p>	<p>One week after VAC Removal (Using P&C, BID) Total Wound Size: Approx. 162 cm > 50% Reduction in Size</p>	<p>Necrotizing Fasciitis Healed in 3 weeks Rx: Pure&Clean HOCl (BID)</p>
--	--	--