

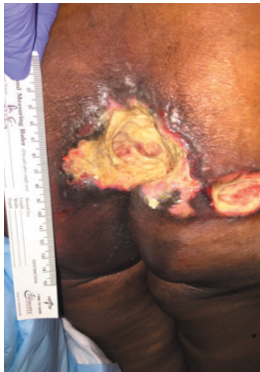
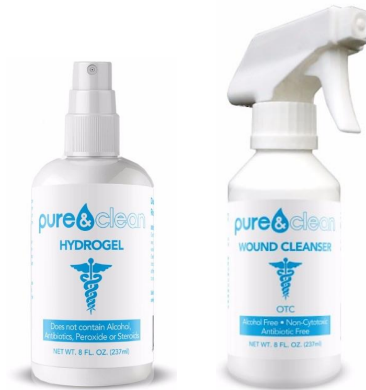
Safe ♦ Effective ♦ Trusted

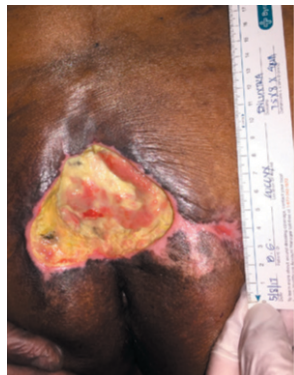Case Study

Using Pure&Clean Wound Cleanser and Hydrogel BID

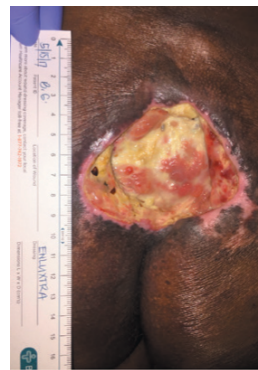
- Sacral Wound – Chronic Pressure Injury
- Two months of treating with traditional wound care showed little to no progress
- Biofilm gone after **only 1 month** with Pure&Clean



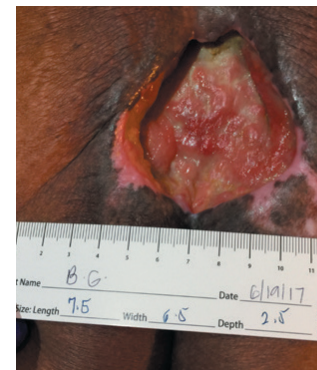Initial wound, traditional wound care started 03/08/17



Progress after 2 months of traditional wound care. Before first application of Pure&Clean. 05/13/17



Progress after one application of Pure&Clean 05/15/17



Biofilm gone after 1 month using Pure&Clean 06/19/17