



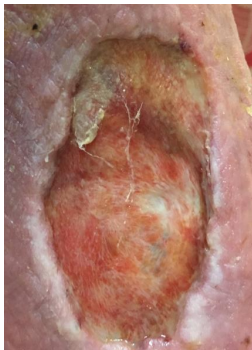
Safe Effective Trusted

Case Study

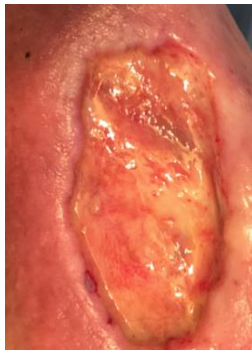
Using Pure&Clean
Wound Cleanser
and
Hydrogel BID



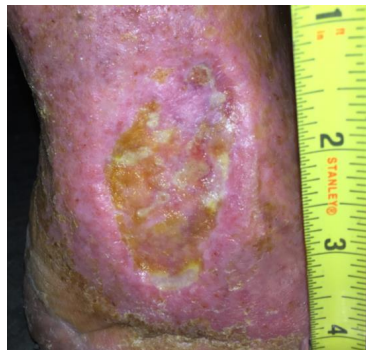- 86 year old female
- Ankle Wound – Pyoderma Gangrenosum
- After **four years** of treating using Santyl, honey, silver products, alginates, Aquacel Ag, Bactroban, sharp debridement, etc.
- Positive biopsy for PG, Autoimmune disease (lupus) common comorbidity associated with PG
- A home health, wound-care nurse treated 1.5 years
- Patient now self-treating
- Occasional visit to rheumatologist 40 mg of oral steroids
- Wound **healed in only 5 months** with Pure&Clean



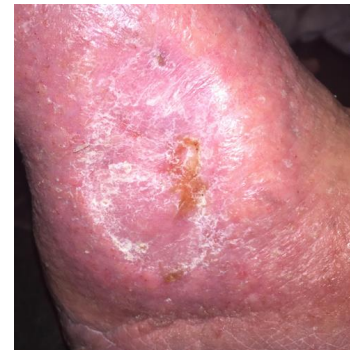Before starting Pure&Clean
09/28/17



Two weeks later
10/12/17



Less than 4 months after starting P&C
01/18/18



Chronic wound healed using Pure&Clean
03/05/18